

Action of a silk fabric treated with AEGIS™ in children with atopic dermatitis: A 3-month trial

Koller DY, Halmerbauer G, Böck A, Engstler G. Action of a silk fabric treated with AEGIS™ in children with atopic dermatitis: a 3-month trial.

Pediatr Allergy Immunol 2007; 18: 335–338.

© 2007 The Authors

Journal compilation © 2007 Blackwell Munksgaard

Irritation of the skin of patients with atopic dermatitis by contact with rough fibres of synthetic or woollen clothes is well known. Therefore, it has been recommended that patients should wear cotton clothes.

However, cotton also consists of rough fibres able to irritate the skin, whereas silk is characterized by smooth fibres without irritating potential. The aim of our study was to evaluate the clinical effect of Dermasilk® – a special silk fabric (sericin-free silk treated with AEGIS AEM5772/5 which has antibacterial properties) – in children with atopic dermatitis. A total of 22 children with mild-to-moderate atopic dermatitis were recruited for a study period of 3 months. All of them received three different tube-fabrics – Dermasilk, sericin-free silk fabric without AEGIS AEM 5772/5 and cotton, covering the cubital region. Patients were advised to wear the Dermasilk fabric all day long during the whole study period on one arm, whereas the sericin-free AEGIS-free silk tube had to be used during the first 2 wk only on the other arm followed by the use of the cotton tube for the rest of the study period. Evaluation of the local SCORAD score was carried out at the beginning of the study, after 2, 4, 8 and 12 wk. A significant reduction of the local SCORAD index of the Dermasilk covered arm was observed after 4, 8 and 12 wk in comparison with the cotton-covered arm score [median (quartile 1–quartile 3)] 6.5 (5–8) vs. 8 (7–9), $p < 0.002$; 6 (5.25–7.75) vs. 8 (7–9), $p < 0.0001$; and 6 (5–6) vs. 8 (7.25–10), $p < 0.0001$. The use of Dermasilk has a significant beneficial effect in atopic dermatitis because of the non-irritating properties of silk as well as the antibacterial capacity of AEGIS AEM 5772/5.

D. Y. Koller, G. Halmerbauer, A. Böck and G. Engstler

Paediatric Ambulatory Care Unit, Department of Paediatrics, Medical University Vienna, Vienna, Austria

Key words: atopic dermatitis; silk; quaternary ammonium compound; antibacterial properties

Dieter Koller, Paediatric Ambulatory Care Unit, Department of Paediatrics, Medical University Vienna, Währinger Gürtel 18-20, A-1090 Vienna, Austria

Tel.: +43 1 40400 3229

Fax: +43 1 40400 3238

E-mail: dieter.koller@meduniwien.ac.at

Accepted 26 October 2006

Atopic dermatitis is a common, chronic or chronically relapsing, inflammatory skin disorder. Despite many reports that immunological disturbances contribute to many manifestations (1, 2), the pathogenesis is still unclear. However, the clinical manifestations of atopic dermatitis seem to depend on a complex inter-relationship among morphological findings and immunological, genetic, physiological and pharmacological factors.

In addition, abnormal bacterial colonization, in particular with *Staphylococcus aureus*, of the

atopic skin has been described as an important factor to maintain skin eruptions in atopic dermatitis (3, 4). Systemic antibiotics are often used in short-term therapy to treat atopic dermatitis, with good results to control flares. Occasionally, long-term systemic antibiotics are beneficial, but they often select for methicillin-resistant strains.

Nonetheless, despite immunological factors and bacterial colonization contributing to worsening of the skin symptoms in atopic dermatitis, an important factor – but often

underestimated – is the use of clothing material. It is accepted that the use of wool or synthetic acrylic clothing results in worsening of itching and skin eruptions in atopic dermatitis. Subjects with atopic dermatitis are thus advised to wear cotton fabrics. However, microscopic examination demonstrated also a harsh fibre, whereas in contrast silk is shaped like a cylinder without any skin-irritating properties. Silk contains two major proteins – fibroin and sericin. The latter protein has been assumed to be responsible for skin irritation and allergies (5). Therefore, in an attempt to reduce the skin-irritating or -sensitising potency of silk, a sericin-free silk product has been developed. To combine the skin non-irritating properties of this silk product with antibacterial qualities, it has been treated with AEM 5700/5772 (3-trimethylsilylpropyl-dimethyloctadecyl ammonium chloride), also called AEGIS™ (AEGIS Environments, Laboratory and Technical Services, MI, USA) which is registered as Dermalilk®. AEGIS™ is a quaternary ammonium compound used on textiles (cotton/polyester sheeting, carpeting and throw rugs, outerwear fabrics, underwear, nylon hosiery, mattress ticking and filter fabrics) demonstrating antibacterial and antifungal properties (6). Action against many bacteria has been described, especially against *S. aureus*, but normal skin flora appears to be unaffected (6). AEGIS™ acts by destruction of the bacterial cell membrane via ion exchange.

We investigated in a 3-month trial whether Dermalilk is able to control skin manifestations in children with atopic dermatitis.

Materials and methods

Patients

This is a blinded randomized study of efficacy in children with atopic dermatitis, which compared Dermalilk® (see below) and cotton wool fabrics. A total of 22 children (11 males, 11 females; age: mean 8.1 yr, range 5–12 yr) with mild-to-moderate atopic dermatitis, diagnosed according to the criteria of Hanifin & Rajka (7) were enrolled. Patients' and parental agreement were obtained in all cases.

The patients were randomized by age group and by disease severity. During the whole study period, only systemic antihistamines and emollients were allowed. Exclusion criteria were the use of topical or systemic antibiotics and also the use of anti-inflammatory agents.

Assessment of disease severity

The severity of local skin involvement (i.e. cubital region) was measured by a modified SCORAD index (8) before starting (visit 1), after 2 (visit 2), after 4 (visit 3), after 8 (visit 4) and after 12 (visit 5) weeks.

The highest intensity score (including erythema, papulation, exsudation, abrasions, lichenification and xerosis) was 18 and the highest subjective score was 10.

The investigator performing the clinical examination did not know which arm had been covered by Dermalilk®. Clinical evaluations were carried out always by the same medical blinded doctor.

Study design

Patients received different 'arm tubes' – cotton, silk and Dermalilk® – fabric (kindly provided by AL.PRE.TEC.; S.Dona di Piave, Venice, Italy) from an unblinded investigator. For the first 2 wk of the study, parents were advised to dress one arm of their children with the simple silk fabric and the other one with the Dermalilk® fabric. After 2 wk – throughout the rest of the study – one arm had to be covered with the cotton and the other with the Dermalilk® tube.

Parents were instructed of the characteristics of Dermalilk® as well as the importance of dressing the arms all day long for the whole study period. In addition, parents were advised to wash the tubes daily.

Statistical analysis

Results are presented as median (quartile 1–quartile 3), unless stated otherwise. Differences were detected by the Wilcoxon signed rank test and the two-tailed paired *T*-test.

The level of significance was considered at the fifth percentile.

Results

During the whole study period, none of the patients used antibiotic or anti-inflammatory agents – neither topically nor systemically. In addition, no adverse reaction to Dermalilk® was reported or observed.

Clinical evaluation

At the beginning of the study, both intensity and subjective scores of both cubital areas were statistically not different (Tables 1 and 2). After

Table 1. Intensity score after 2, 4, 8 and 12 wk in 22 children with atopic dermatitis. Results are presented as median (quartile 1–quartile 3)

	Dermasilk-covered arm	Simple silk/cotton-covered arm	p-value
Week 0	9 (8–12)	9.5 (8.25–11.5)	0.355
Week 2	7.5 (6–9)	8 (6.25–9.75)	0.274
Week 4	6.5 (5–8)	8 (7–9)	0.002
Week 8	6 (5.25–7.75)	8 (7–9)	0.0001
Week 12	6 (5–6)	8 (7.25–10)	0.0001

Table 2. Subjective score after 2, 4, 8 and 12 wk in 22 children with atopic dermatitis. Results are presented as median (quartile 1–quartile 3)

	Dermasilk-covered arm	Simple silk/cotton-covered arm	p-value
Week 0	5 (4–7)	5 (5–7)	0.427
Week 2	5 (4–5)	4 (4–5)	0.051
Week 4	4 (2.25–4)	5.5 (5–6.75)	0.0002
Week 8	3 (2–4)	5.5 (5–6)	0.0001
Week 12	3 (2–4)	6 (5–7.75)	0.0001

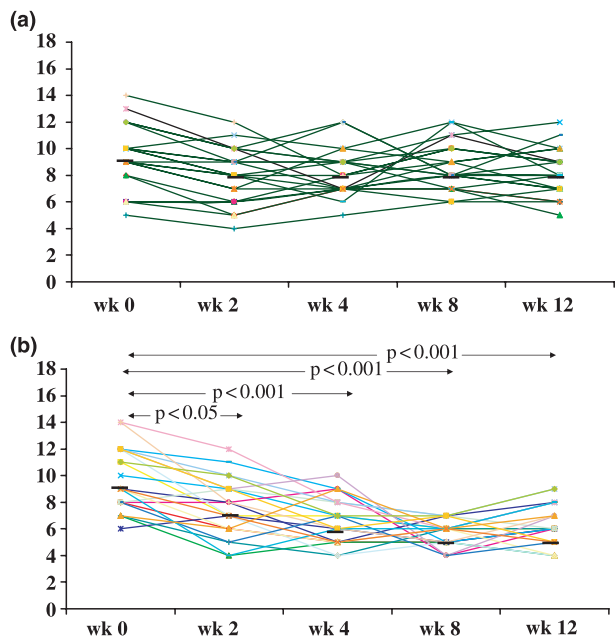


Fig. 1. Intensity score during the study period on the simple silk/cotton-covered arm (a) and on the Dermasilk-covered arm (b).

2 wk, the intensity score of the Dermasilk®-covered area significantly decreased ($p < 0.05$; Fig. 1; Tables 1 and 2), whereas the subjective score did not change (Fig. 2; Tables 1 and 2). However, changes were not significant when compared with the simple silk or cotton covered arm. Nonetheless, significant clinical improvement was observed within and between the

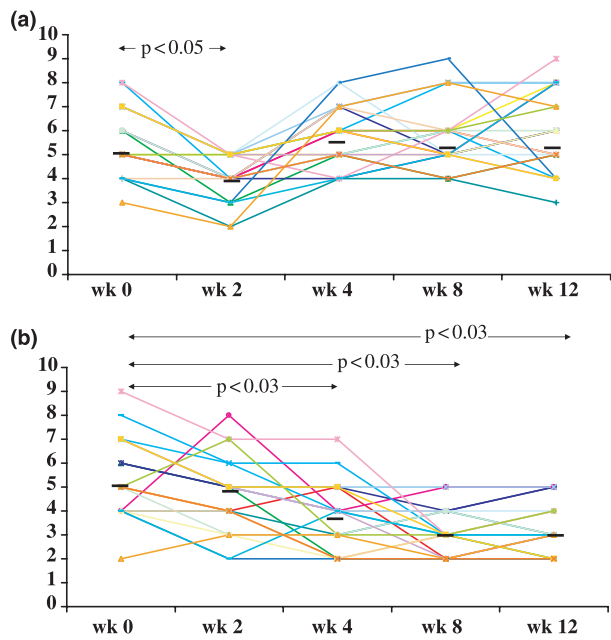


Fig. 2. Subjective symptom score during the study period on the simple silk/cotton-covered arm (a) and on the Dermasilk-covered arm (b).

Dermasilk®- and cotton-covered arms after 4, 8 and 12 wk (Figs 1 and 2; Tables 1 and 2).

Discussion

Our study demonstrated a significant clinical improvement of mild-to-moderate atopic dermatitis by covering affected skin areas with Dermasilk which presents the first silk product successfully covered with AEGIS™. This is in agreement with a short-term (1 wk) study (9), the positive effect of Dermasilk®.

Natural silk – secreted by the silk worm – consists of a single-thread silk that is increasingly used in the treatment of skin disorders because of its unique properties, like its smoothness. However, natural silk contains the protein sericin that possesses a high sensitizing capacity (10).

It has been demonstrated that clothes made of softened fabrics have a beneficial effect on the skin of atopic dermatitis patients (11). Moreover, silk-covered wounds healed faster than non-silk-covered skin areas, which has been explained by the fact that silk enhances collagen synthesis and reduces inflammatory processes (12). Usual silk fabrics used for clothes are not recommended for dressing of subjects with atopic dermatitis, as these fabrics reduce transpiration and therefore may cause worsening of disease activity.

Dermasilk® is a new silk fabric of high quality characterized by being sericin-free – as certified

by the Stazione Sperimentale per la Seta Milano (9) – to reduce any sensitizing properties of silk. In addition, this silk fabric allows not only adequate skin breathing but also absorption of sweat, which is important to maintain the water balance of the skin. Furthermore, Dermsilk[®] is treated with AEM 5700/5772 (3-trimethylsilylpropyl-dimethyloctadecyl ammonium chloride), also called AEGIS[™], which is a quaternary ammonium compound. Until now, AEGIS has been used on other textiles, like cotton/polyester sheeting, carpeting and throw rugs, outerwear fabrics, underwear, nylon hosiery, mattress ticking and filter fabrics. Antibacterial and antifungal capacity of quaternary ammonium compounds is known since approximately 50 yr (6). As many patients with atopic dermatitis are colonized with *S. aureus* (3), it might be speculated that the beneficial effect of Dermsilk[®] in our study is also because of the antibacterial properties of AEGIS[™], despite its skin non-irritating properties.

Silk allergy has been reported, especially in silk workers, which is caused by sericin, as we also focused on adverse reaction to Dermsilk[®]. However, in previous studies, as also in our study, no adverse effects were observed or reported by the parents. We also demonstrated that the effectiveness of Dermsilk[®] is not reduced by laundering, although the tubes were washed daily. However, according to the manufacturer's instructions, the garments must be worn all day long.

In conclusion, Dermsilk[®] is useful in the treatment of mild-to-moderate atopic dermatitis in children. The effectiveness is because of the characteristics of this new fabric: (i) smoothness without skin-irritation, (ii) no sensitizing capacity because of it being sericin-free, (iii) maintenance of water balance of the skin and absorption of sweat and (iv) antibacterial and antifungal properties because of the water-resistant treat-

ment with AEGIS. Furthermore, the effect of Dermsilk[®] in severe atopic dermatitis and also its potential anti-inflammatory agents-sparing effect need to be evaluated.

Acknowledgment

We extend our thanks to AL.PRE.TEC., S.Dona di Piave, Venice, Italy as well as to Menzl GesmbH, Vienna, Austria for providing cotton, silk and Dermsilk fabrics.

References

1. HANIFIN JM. Atopic dermatitis. *J Allergy Clin Immunol* 1984; 73: 211–22.
2. HALMERBAUER G, FRISCHER T, KOLLER DY. Monitoring of disease activity by measurement of inflammatory markers in atopic dermatitis. *Allergy* 1997; 52: 765–9.
3. LEYDEN JJ, MARPLES RR, KLIGMAN AM. *Staphylococcus aureus* in the lesions of atopic dermatitis. *Br J Dermatol* 1974; 90: 525–31.
4. LEUNG DYM, BIEBER T. Atopic dermatitis. *Lancet* 2003; 361: 151–60.
5. CELEDON JC, PALMER LJ, XU X, et al. Sensitization to silk and childhood asthma in rural China. *Pediatrics* 2001; 107: E80.
6. GETTINGS RL, TRIPLETT BL. A new durable antimicrobial finish for textiles. *AATCC Book of Papers* 1978: 259–61.
7. HANIFIN JM, RAJKA G. Diagnostic features of atopic dermatitis. *Acta Derm Venereol Suppl (Stockh)* 1980; 92: 44–7.
8. Severity Scoring of Atopic Dermatitis: the SCORAD Index. Consensus report of the European Task Force on Atopic Dermatitis. *Dermatology* 1993; 186: 23–31.
9. RICCI G, PATRIZI A, BENDANDI B, MENNA G, VAROTTI E, MASI M. Clinical effectiveness of a silk fabric in the treatment of atopic dermatitis. *Br J Dermatol* 2004; 150: 127–31.
10. HARINDRANATH N, PRAKASH OM, RAO PVS. Prevalence of occupational asthma in silk filatures. *Ann Allergy* 1985; 55: 511–5.
11. HERMANN JF, GON V, ARRESE JE, et al. Beneficial effects of softened fabrics on atopic skin. *Dermatology* 2001; 202: 167–70.
12. SUGIHARA A, SUGIURA K, MORITA H, et al. Promotive effects of a silk film on epidermal recovery from full-thickness skin wounds. *Exp Biol Med* 2000; 225: 58–64.